

# Fiber Post Techniques for Anatomical Root Variations



Leendert (Len)  
Boksmans DDS,  
BSc

Alejandro  
Bertoldi  
Hepburn, DDS

Enrique Kogan,  
DDS

Manny  
Friedman, BDS,  
BChD

Waldemar De  
Rijk, PhD, DDS

The purpose of this article is to identify and describe the newer materials and techniques deemed as viable alternatives to metallic post/cores, and to propose a rationale for the selection of one product or restorative technique protocol over others for simple and complex post-endodontic restorations. These are indicated where remaining coronal tooth structure is less than 50% and/or the core strength is compromised by the endodontic access opening.

## BACKGROUND

Custom cast posts were first described more than 100 years ago, and utilized the optimal impression techniques, casting, and cementation materials available at that time. In most of the world, cast posts (still taught in some dental schools) have been supplanted in clinical practice by prefabricated posts made either of metallic alloys or from fiber-reinforced composite. In even a cursory review of the literature, the evidence-based support for a trend away from metal posts to fiber posts is abundant and conclusive:

- Fiber posts, regardless of brand, are anisotropic and have a modulus of elasticity similar to that of dentin (~20 GPa), which allows the post to flex slightly (microscopically) with the tooth and dissipate stress, thereby reducing the likelihood of damage to the root.<sup>1-4</sup>

- Fiber posts are *not* susceptible to galvanic or corrosion activity; the latter of which is responsible for a high percentage of failures with cast posts<sup>5</sup> which, in turn, fail twice as often (clinically) as do prefabricated metal posts.<sup>6</sup>

- Fiber posts are available in translucent and tooth-colored versions (the original black carbon posts are passé), which are aesthetically invisible under all ceramic crowns, veneers and resin restorations, and also mitigate the effects of the dark root syndrome (Figure 1).<sup>7,8</sup>

- Fiber posts (excepting a South American post design that has a metal wire running through its long axis) are more easily and safely removed “by hollowing them out from the inside,” should re-treatment ever become necessary.<sup>9-12</sup> In fact, cemented metal posts may further limit or complicate endodontic treatment options if these become necessary.<sup>13</sup>

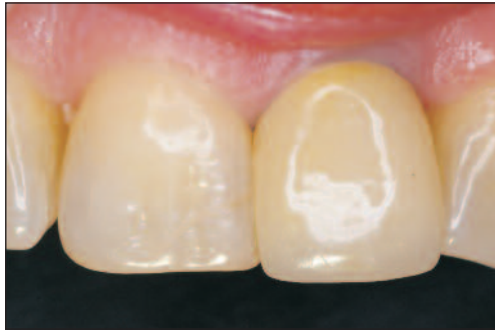

Figure 1. Typical gingival darkening created by metal post and core technique.




Figure 2. Cross section of a good quality post which is highly loaded with fibers with no voids.




Figure 3. Cross section of a poor quality post showing lower fiber loading with voids in the matrix.

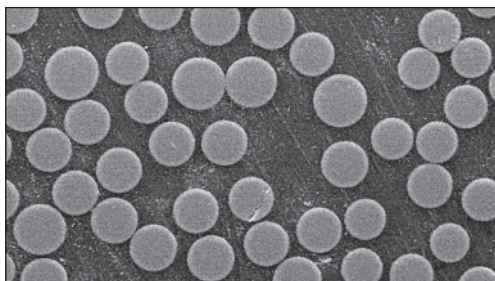


Figure 4. Cross section of a fiber post with low fiber and high resin matrix content.

While all brands of fiber posts appear to have these commonalities, they are not all the same; they can vary considerably from brand to brand in terms of composition and microstructure. The difference in the manufacturing process of the posts can significantly

influence their mechanical properties,<sup>14,15</sup> and thus their clinical performance. Furthermore, a connection can be found between the data obtained with SEM observations of fiber posts and their clinical behavior. SEM photographs (Figures 2 to 4), taken at the same (700x) magnification, show the variations in size of fiber, orientation, number of fibers, amount of composite, and the relative percentages which varies from fiber post to fiber post. In fact, posts that have more imperfections in the matrix will have a less compact and even structure, and thus are weaker and less resistant to load stress.<sup>14</sup>

Increases in the mechanical properties (fracture strength) appear directly proportional to the density of fibers and to their interface/bond to the matrix.<sup>16</sup> In addition to influencing flexural strength, the fiber type, density, and uniformity of microstructure also affect the radiopacity and fatigue resistance. Figure 5 shows the relative radiopacity of various fiber posts side by side, and Figures 6 to 8 demonstrate the same variation in an extracted tooth that is prepared for a 1.5 mm tapered fiber post. It is obvious that the Macro-Lock Illusion X-RO (RTD [CLINICIAN'S CHOICE]) is the most radiopaque in this sampling of fiber posts (Figure 7).

Quartz fibers are among the most radiopaque fibers being used,<sup>17,18</sup> and the quartz fiber posts have proven superior in fatigue resistance to glass fiber posts<sup>15</sup> and to metal posts.<sup>19</sup> Fatigue tests can be considered as the most relevant methodological standard for evaluating and predicting the behavior in an oral environment.<sup>18</sup> The *in vitro* studies that more than any other permit the fair prediction of yielding and, therefore, the long-term behavior of the restoration, are the fatigue tests.<sup>20,21</sup>

Into the 1970s, it was hoped that metal posts could help reinforce weakened endodontically-treated teeth. In the 1980s, Sorensen, et al surmised otherwise. Today there is a growing body of *in vitro* evidence that if properly placed, low modulus restorations (quartz fiber posts with bonded composite cores) with varying amounts of remaining tooth structure can, in fact, provide some restrengthening of weakened teeth restored

*continued on page xx*

### Fiber Post Techniques...

continued from page 00

with MOD restorations, veneers or full coverage techniques.<sup>22-26</sup> Figure 9 shows a high-power SEM of the adaptation possible with an appropriately sized bonded fiber post creating a “monoblock.” A ferrule of 2 mm has to be provided for the reconstruction of endodontically treated teeth by post and core techniques. (Studies show that increasing the length of a ferrule from 1 to 1.5 mm in a quartz fiber post does not significantly increase fracture loads, but an increase to 2 mm results in higher fracture thresholds.)

Now the clinical observation of carbon<sup>27-30</sup> or glass and quartz fiber<sup>31-34</sup> post restorations offer admirable performances at 7 to 11 years’ conclusion,<sup>35</sup> and the difference in failure rates—particularly catastrophic failure rates—between fiber posts and cast posts is no less compelling at 4 years’ service.<sup>36</sup>

The placement of a single fiber post in a relatively “round” and minimally tapered conservative root canal has been described in many articles and is now appearing in textbooks. There is evidence that (unlike metal predecessors) there is no difference in the performance between tapered and parallel fiber posts.<sup>37,38</sup> However, it is self-evident to an experienced clinician that parallel posts may often require the removal of additional dentin and the creation of acute internal angles (“stress magnets”). There-

fore, the tapered apical/parallel body shape is preferable<sup>39-41</sup> if only for the sake of dentin conservation. Figures 10 and 11 show the same tooth as above, prepared for a tapered 1.5 mm fiber post. It is obvious from the radiographs that more tooth structure at the apical end of the canal would need to be sacrificed to allow the parallel 1.5 mm posts to seat to the same length, needlessly weakening the remaining root structure.

So, then, what is the contemporary technology protocol, when faced with a flared, ovoid, or figure-8 canal?

Circular parallel post systems are only effective in the most apical portion of the post space, because the majority of prepared post spaces demonstrate considerable flare in the coronal half. Similarly, when the root canal is elliptical, a parallel-sided post will not be effective unless the canal is considerably enlarged,<sup>42</sup> thereby needlessly removing extra dentin. From a clinical perspective, when assessing posts that have failed, many are in fact cemented or bonded to areas in the canal still occupied by gutta-percha. One of the causes for the lack of resultant retention is due to this oversight, which is a direct result of preparing a round canal space with a rotary instrument in a canal which is never round. There are 2 prefabricated posts available (in limited market areas) that are designed with a rounded, tapered apical extremity, and an oval coronal section (PeerlessPost [SybronEndo] and ELLIPSON [RTD]).

The low modulus approach needs to be adaptable to the over-flared canal, while addressing the inherent challenges, which include C-factor stress and S-factor stress,<sup>43</sup> polymerization shrinkage and, presumably, microleakage.

Most fiber posts on the market come in cylindrical sizes that mimic their metallic ancestors, so that the practitioner may use the drills already purchased. However, as previously discussed, a tapered preparation is the most noninvasive. Unlike fiber posts, as the diameter of metal posts increases, so does the stress transfer to the tooth,<sup>44</sup> and so, logically, does the likelihood of root splits.

There are some tapered quartz fiber posts that come in extra large sizes that range from 0.8 mm at the apical tip to 2.3 mm at the coronal extreme (DT Light-Post [RTD, BISCO] and Macro-Lock Post [RTD]). These sizes exceed the diameters available in most brands, and are capable of fitting most root canal treatments without further instrumentation.

The authors will now describe and suggest an approach and technique for the inevitable variations presented by prepared and filled root canals which fall into 3 proposed treatment categories.


### THE SIMPLE CANAL

In a “simple” case, where the canal treatment results in the typical tapered conservative shape (*less than 25% larger than the fiber post* [Figure 12]), a single fiber post can be inserted


and covered with a composite core build-up in preparation for the prosthetic restoration. The clinical protocol for this type of case is as follows:

All procedures inside the root canal should focus on the bottom-up approach; the canal is prepared with the matching sized post drills and posts, and all remnants of gutta-percha must be removed from the walls of the post space to facilitate bonding. The fiber post is generally shortened to the height of the core with a diamond bur before the bonding procedure is started, but it can also be cut with a diamond bur after the core is cured. If using a self-curing resin cement, the post should always be cut to length first, so as not to vibrate the post while the cement may be setting. Fiber posts can be cut to length after the core is placed, but color changing posts are unique. A color changing post should be cut 1.5 mm short of the anticipated coronal extent of the core, and thus be buried in the core composite. This is done to prevent reappearance of the color under translucent ceramics due to exposure to intraoral temperature changes when the patient ingests cold beverages or food. The clinical presentation and treatment of a case that is typical for the simple canal is shown in Figures 13a to 13o. The tooth is isolated and gutta-percha is removed with a small starter drill (Figure 13b), and the post space is created with the appropriate size taper drill (Figure 13c). Care


continued on page xx




**Figure 5.** Radiograph of various shapes, designs, tapers of early radio-apparent fiber posts.




**Figure 6.** Radiograph of typical fiber post when prepared for a 1.5 mm taper.



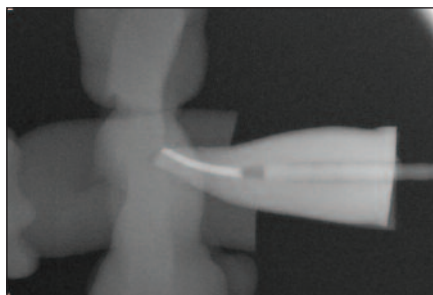
**Figure 7.** The Macro-Lock Illusion X-RO (CLINICIAN'S CHOICE) shows excellent radiopacity at 1.5 mm post space preparation.



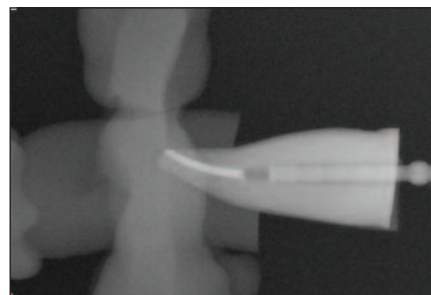
**Figure 8.** Same tooth radiographed with a popular radio-apparent fiber post.



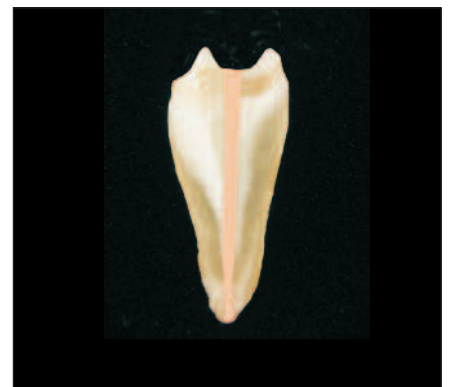**Figure 9.** Scanning electron microscope photograph of intimate adaptation of fiber post, dual cure resin cement and root dentin.



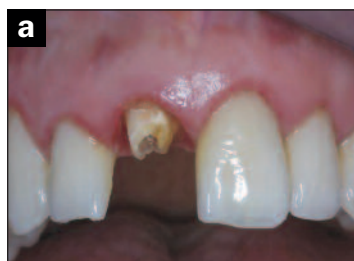**Figure 10.** Parallel-sided fiber post of 1.5 mm does not seat in same tooth without more apical removal of dentin structurally weakening the tooth.



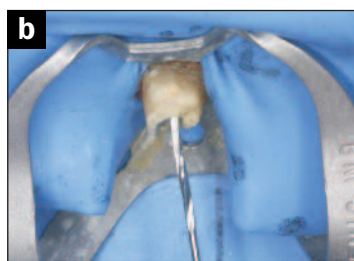**Figure 11.** 1.5 mm parallel post with lateral serrations and core bulk again requires more apical dentin removal to seat to same length as the tapered Macro-Lock Illusion X-RO (compare to Figure 7).



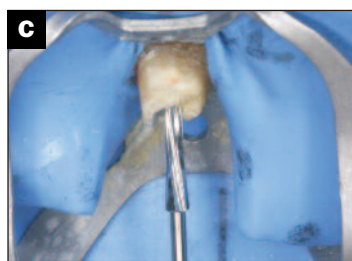**Figure 12.** A conservative nonflared canal is ideal for a conservative flared fiber post preparation.



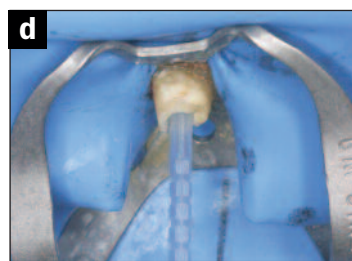
**Figure 13a.** Clinical presentation of failed post and core crown on upper right central incisor.



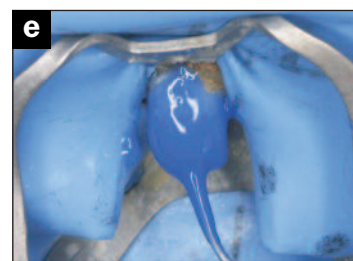**Figure 13b.** A small starter drill is used to initiate removal of the gutta-percha.



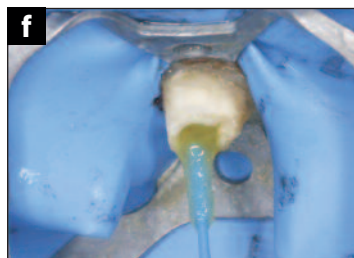**Figure 13c.** The appropriate size tapered Macro-Lock drill is used to maximize size while minimizing dentin removal.



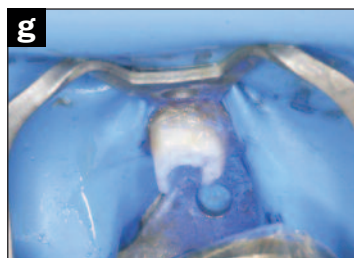
**Figure 13d.** The Macro-Lock X-RO post inserted and checked for fit. Notice the small space between the post and the walls of the post preparation. A diamond is then used to shorten the post to the desired length.



**Figure 13e.** An acid gel (Ultra-Etch [Ultradent Products]) is injected from the bottom of the post space up to the cavosurface margin by using a 20 or 22 gauge needle to avoid air entrapment.



**Figure 13f.** After water rinsing from the bottom of the canal up, and light drying, the canal is checked for excess moisture with a paper point; the bonding agent is placed in the canal and lightly agitated to increase the bond strength to the dentin.



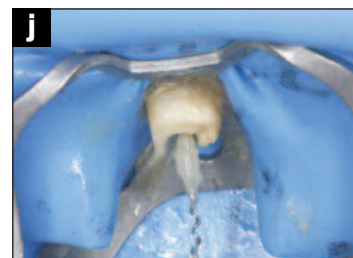
**Figure 13g.** After air thinning the bonding agent from the bottom up, the canal is checked for excess bonding agent with a paper point, and the bonding agent is cured with a high output curing light for 20 seconds.



**Figure 13h.** The bonding agent is applied to the post with a microbrush.



**Figure 13i.** After evaporating the solvent and air thinning, the bonding agent is light-cured.



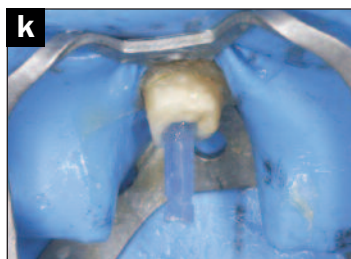
**Figure 13j.** Using a lentulo-spiral to insert the dual cure resin cement will accelerate the set. It is best to inject using a 20 to 22 gauge needle (Endo-Eze [Ultradent]) from the bottom up to eliminate air entrapment.

### Fiber Post Techniques...

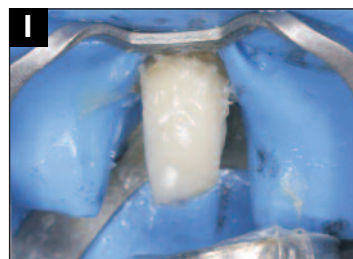continued from page 00

should be taken to match the post, as close as possible, to the size of the existing canal space rather than over preparing the canal for a large post. At this time, all remnants of gutta-percha should be removed and verified visually with magnification.

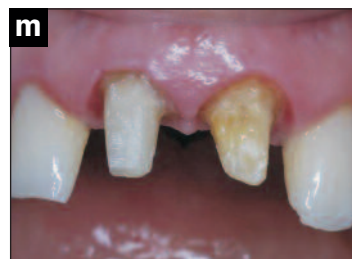(Some practitioners use chloroform to dissolve any remaining gutta-percha in the post space area.) The fiber post (Macro-Lock X-RO [RTD, CLINICIAN'S CHOICE]) is tried in the canal (Figure 13d). Then, it is trimmed to length with a diamond bur to prevent chatter and possible damage to the post. To decontaminate the post after try-in and length adjustment, it is cleaned with alcohol prior to bonding. The canal is acid etched by placing the acid gel from the bottom up using a 20- or 22-gauge needle tip (Figure 13e). This is done to keep an air lock from forming below the etchant, which would prevent etching of the entire canal space. It has been shown that agitating the acid with a microbrush during this 15-second procedure increases bond strength. The canal is rinsed with water, again from the bottom up, using a 20- or 22-gauge needle adapted to either a Stropko Irrigator (CLINICIAN'S CHOICE) or TriAway Adaptor (Ultradent Products), to thoroughly



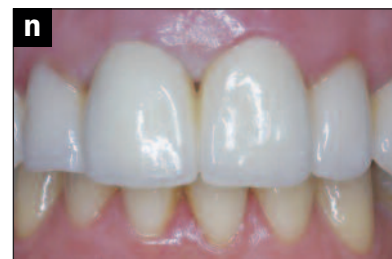**Figure 13k.** After insertion of the fiber post into the dual cured resin cement and placed to length, the cement is cured with light down the long axis of the fiber post for 30 seconds.



**Figure 13l.** After injecting and hand sculpting the core material around the remainder of the fiber post, the composite resin is light-cured.



**Figure 13m.** The clinical preparation of the fiber post and core for full coverage restoration is shown in this intraoral photograph.



**Figure 13n.** The final ceramic restorations (Zirconia [ZirconZahn]) on the 2 upper central incisors.

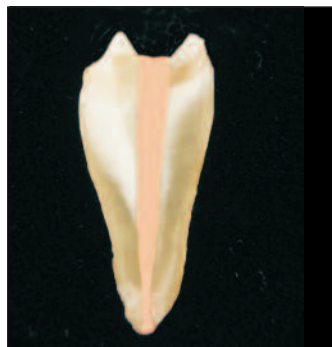wash and remove the acid gel out of the canal space. This cannot be achieved with a typical 3-way syringe, which can leave some acid in the canal, interfering with the chemical setting reaction of a dual- or self-cure cement. The canal is lightly dried using air from the bottom up and then double checked with a paper point. The adhesive bonding agent is placed with a microbrush and agitated into the opened tubules of the root canal (Figure 13f). Air is delivered from the bottom up and excess bonding agent and pooling is prevented by inserting a paper point to absorb any excess. The bonding agent is then light-cured with a high-power, broad spectrum LED curing light for at least 30 seconds (Figure 13g). It must be remembered that light intensity for some curing lights falls drastically with distance, so the cure must be adequate. There are only 3 possible solutions for this: (1) a dual

(photo and chemical) activation adhesive, (2) conducting the light through the post and photoactivate it together with the resin cement, or (3) light-curing adequately with a high-power light (such as the VALO [Ultradent Products]) in its plasma emulation mode, 3 seconds at over 3,000 mW/cm<sup>2</sup>. The point here is that if light-cured adhesives are used, undercuring will lead to failure. Next, bonding agent is applied to the post (Figure 13h) and light-cured (Figure 13i). Then, after the dual cure resin cement is placed into the canal with Skini Syringe mated to an Endo-Eze tip (Ultradent) (Figure 13j), the post is inserted and the dual cure resin cement is light-cured for 30 seconds (Figure 13k). It is best to inject the dual cure resin cement from the bottom up rather than using the lentulo-spiral. This prevents any possible air entrapment and prevents the acceleration of set caused by the lentulo-spiral drill. The core material is injected around the post, and then light-cured (Figure

13l). The final preparation of the core for the patient is shown in Figure 13m and the final Zirconia (ZirconZahn) (ceramic) restorations are shown in Figure 13n.

There are many recommendations being made for the selection of cementation media and placement technique. Standard bonding tests would support the use of a fourth or fifth generation adhesive system (ie, All-Bond 2 [BISCO] or One-Step [BISCO], SealBond Ultima [RTD], MPa [CLINICIAN'S CHOICE] respectively) in conjunction with dual-cure or chemical-cure resin cement, as being superior to self-etching or self-adhesive cement formulas.<sup>45</sup> Clinical success with these also assumes proven chemical compatibility between the adhesive and the resin cement, and meticulous isolation, good access, vision, and technique. This is easy in the *in vitro* laboratory, but not always so easy *in vivo*.

continued on page xx



**Figure 14.** A typical cross section of a tooth with a mildly flared canal which results in some excess space around the proposed fiber post in the coronal area.

### Fiber Post Techniques...

continued from page 00

In cases where access and/or visibility and/or good moisture control are compromised, some post manufacturers and clinicians/researchers report good results using self-adhesive, self-etching cements<sup>46-48</sup> and resin-reinforced glass ionomer cements,<sup>49</sup> particularly when using macroretentive quartz fiber posts (Macro-Lock X-RO). However, it should also be noted that some of the comparative in vitro bond strength studies (to dentin) show these newer generations of cements to be inferior to the “total-etch/moist-bonding” dual-cure cementation technique. Furthermore, a post inserted like this should also have high flexural strength (minimum 1,500 MPa) since it won't have the mechanical reinforcement that the adhesive cementation provides.

Because larger, tapered, and even *double*-tapered fiber posts are now offered, and these are mechanically compatible with the remaining tooth structure, good close adaptation of the post to the post space can routinely be achieved, with a minimum of cement thickness,<sup>40,41</sup> thus minimizing the S-factor. It is the more flared spaces that are addressed now.

### THE ANATOMICAL POST AND CORE

Polymerization shrinkage, and the stresses associated with that (the C-factor and S-factor), are a big consideration in all bonding/restorative procedures, and nowhere is the C-factor

higher than it is in post cementation,<sup>43</sup> because of the high number of involved surfaces and unbounded surfaces. Even though composite resin core materials generally have more filler and, therefore, higher strength than resin cements, the polymerization shrinkage stress is higher with 70% filler than that with 10% filler.<sup>50</sup> This may seem counterintuitive to most dentists, but the objective is to utilize a technique that compensates for the inherent *deficiencies* of some materials and, in fact, actually capitalizes on them without becoming clinically cumbersome, time consuming,

or with the integration of outside laboratory fees.

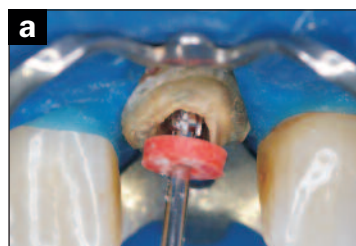
In an earnest attempt to address these factors, Grande<sup>51</sup> and Plotino<sup>52</sup> have described chairside techniques for adapting prefabricated fiber posts to ribbon-like, oval, or ovoid canal spaces by remodeling; in essence, by whittling the post with a diamond bur to match an analog achieved through a separate procedure. The results suggest that the volume of cement is minimized, and the retentive surfaces of the post are not compromised. However, no information is offered regarding the effects that whittling a round (tapered or par-

allel) post brings to the other mechanical properties of the fiber post, such as structural integrity.

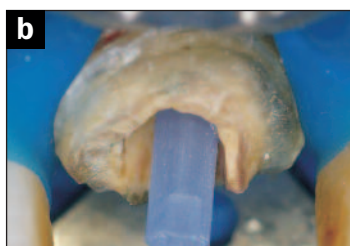In the mildly flared space (Figure 14), we can create a composite “*core build-down*” followed by the core build-up. In the flared canal with a coronal circumference 25% to 50% greater than that of the largest fiber post (by itself) available, the authors suggest the following protocol.

In this clinical case, the canal has a moderate flare with the above criteria. The tooth is isolated, and the canal is prepared as previously with a size

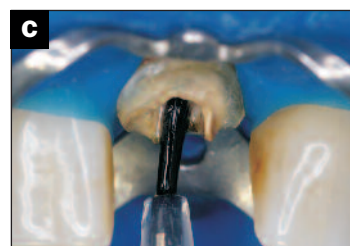continued on page xx



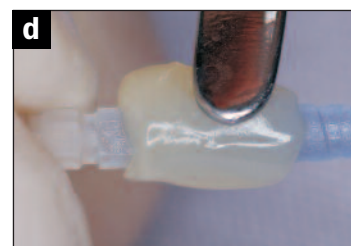
**Figure 15a.** In this type of canal the tooth is isolated and prepared to a post size that will fit at the apical end without overly enlarging the prepared canal.



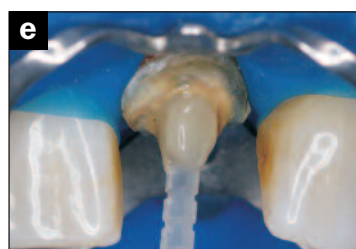**Figure 15b.** The Macro-Lock X-RO post is verified for fit—notice how the canal flares and there is excess space at the coronal aspect.



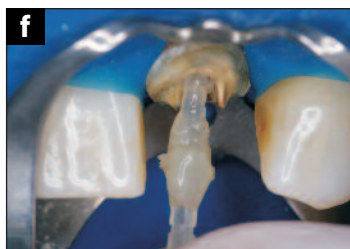**Figure 15c.** Using a brush, a water soluble separating medium is applied to the post space.



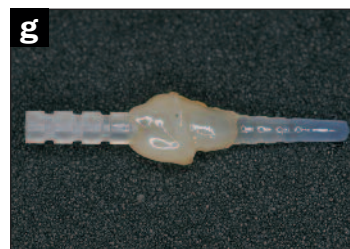**Figure 15d.** A light cured composite (such as Grandio [VOCO]) is adapted to the prebonded post.



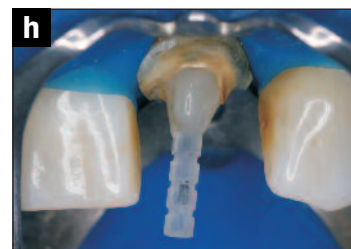**Figure 15e.** The post and hybrid composite are seated into the prepared post space creating a custom post.



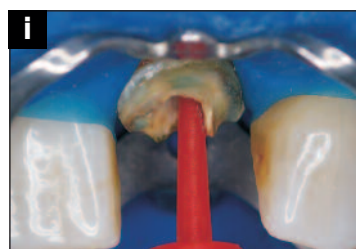
**Figure 15f.** After light-curing, the custom fiber post and core is removed—this mitigates the S factor by allowing the resin to shrink toward the post.



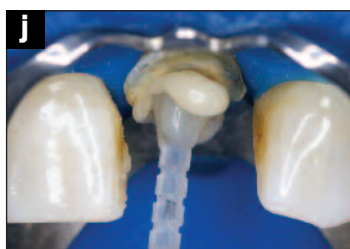**Figure 15g.** The custom fiber post and core is removed.



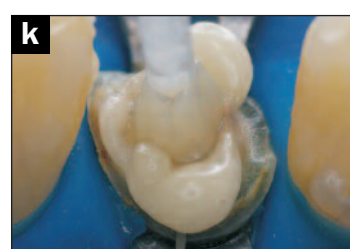
**Figure 15h.** After a thorough rinsing of the prepared canal space and the custom fiber post and core, the core is resealed in the canal and the labial aspect marked with a pencil.



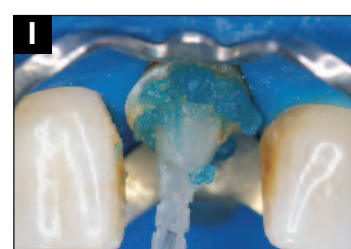
**Figure 15i.** The canal is etched and the etchant is agitated with a micro-brush, rinsed from the bottom up, and a bonding agent is agitated into the dentin and light-cured.



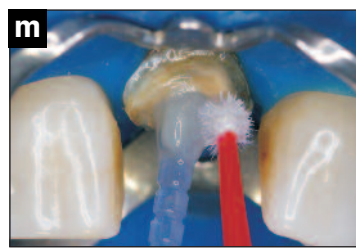
**Figure 15j.** Labial view of Macro-Lock X-RO post inserted into the cement.



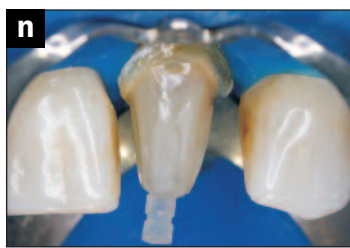**Figure 15k.** The post is seated into the canal with the pencil marking placed labially. The custom posts allow for a minimal thickness of luting cement thus minimizing the S factor. Excess cement is removed before light polymerization.



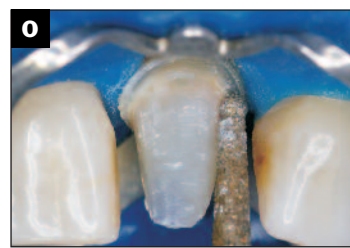**Figure 15l.** The margins of the tooth preparation are refreshed and etched prior to bonding the core.



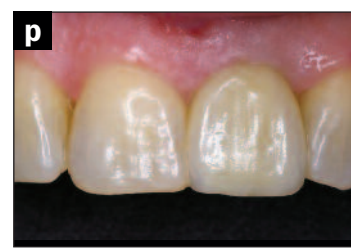**Figure 15m.** Bonding resin is placed on the dentin prior to hand sculpting the composite resin core, then the core build-up is shaped/completed and light-cured.



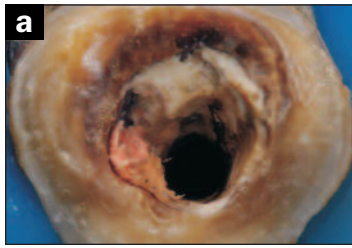
**Figure 15n.** This photograph shows the hand sculpted custom fabricated fiber post and core after hand sculpting and light-curing.



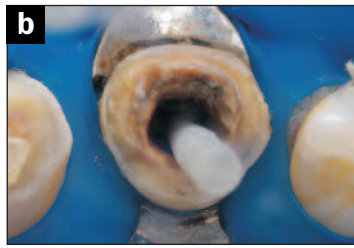**Figure 15o.** The core is finalized with a coarse diamond bur to length and depth requirements for the ceramic crown.



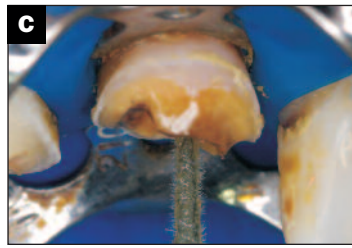
**Figure 15p.** The final ceramic restoration e.maxPress (Ivoclar) with feldspathic overlay over the custom fiber post and core is shown in this photograph.



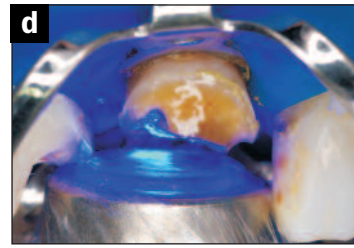
**Figure 16a.** Photo of failed cast post and core with widely flared canal—note the thickness of the prior cement used.



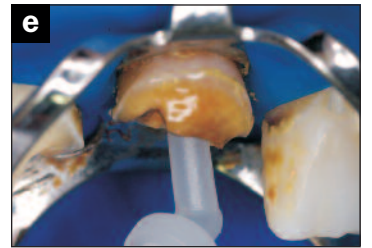
**Figure 16b.** With the gutta-percha and cement removed, no other dentin was removed, and the largest diameter fiber post that fit at the apex was the starting point.



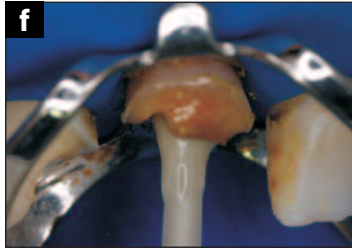
**Figure 16c.** The existing canal space was acid-etched with phosphoric acid for 15 seconds and rinsed from the bottom up with a 20 to 22-gauge needle tip. The bonding resin was agitated into the dentin, air thinned from the bottom up, verified with a paper point.



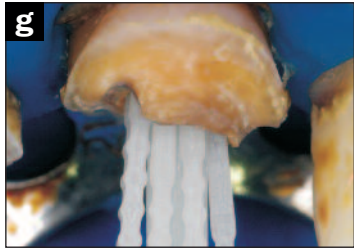
**Figure 16d.** The bonding resin is thoroughly cured with a high output light curing unit.



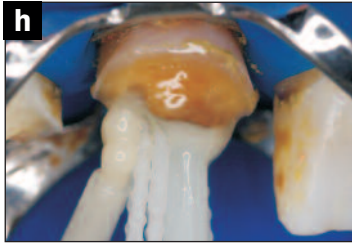
**Figure 16e.** The dual-cured resin cement (Rebuilda DC [VOCO]) is then injected from the bottom of the preparation to the coronal aspect.



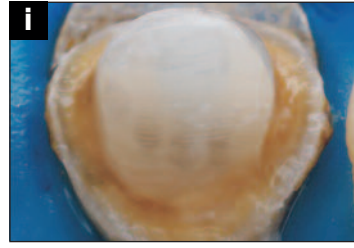
**Figure 16f.** The “master” prebonded post is inserted to length into the dual cure resin cement.



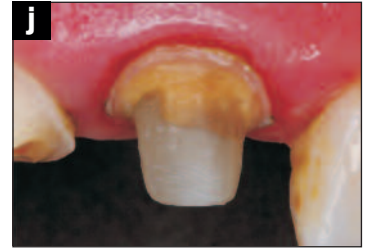
**Figure 16g.** Pre-bonded Fibercones (RTD) are inserted prior to light curing to minimize the amount of dual cure resin and to strengthen the post.



**Figure 16h.** The core composite is injected between and around the Fibercones and central “master” fiber post and hand sculpted prior to light-curing.



**Figure 16i.** The occlusal view of the “reinforced” fiber post and core with rubber dam still in place.



**Figure 16j.** The intraoral clinical view of the “reinforced” fiber post and core with rubber dam still in place, prepared for the full coverage ceramic restoration.

### Fiber Post Techniques...

*continued from page 00*

appropriate drill (Figure 15a). After the canal is thoroughly cleaned, the fiber post is inserted and the fit verified (Figure 15b). A water soluble separating medium is applied to the post space (Figure 15c), a light-curable hybrid composite core material (such as Grandio [VOCO]) is adapted to the pre-bonded post (Figure 15d), which is then inserted into the root canal space (Figure 15e). The composite is light-cured through the light-conductive fiber post, and the post is removed from the canal (Figures 15f and g). When performing this technique, the clinician must look for undercuts before creating the “core build-down.” It won’t be possible to remove the post if cured in those undercuts, and the procedure will have to be repeated, possibly injuring the post. After verifying the position (Figure 15h) by marking the labial with a pencil for orientation, the canal is thoroughly rinsed and the build down is rinsed to remove the water soluble separating medium. As in the first clinical protocol, the canal is etched with a microbrush which is agitated in the canal (Figure 15i), rinsed from the bottom up, dried from the bottom up, and any excess water removed with a paper point. The light-cured bonding agent is applied and fully cured as in the previous protocol. The dual cure resin cement is placed in

the canal, the core build-down is inserted (Figures 15j and 15k), and thoroughly light-cured. After cementation, the dentin is refreshed with a diamond, the surface etched (Figure 15l), rinsed and bonded (Figure 15m); then, the core material is adapted and light-cured. The resultant free-handed core is shown in Figure 15n, which is modified with a tapered coarse round ended diamond (Figure 15o), and the final ceramic crown (IPS e.max [Ivoclar Vivadent]) over the custom-fabricated fiber post and core is shown in Figure 15p.

This way, any shrinkage in the “build-down” is now in free space, not between the tooth and the restoration, neutralizing the S-factor effect. And it assures that the cement thickness will be minimal and uniform.<sup>48</sup> In most cases, the air-inhibited layer on the build-down can remain intact. If in doubt, the excess cement and remaining tooth structure can be refreshed before the bonding agent and core build-up composite is applied.

It is a direct-indirect technique, and has shown optimistic results.<sup>53-55</sup>

### THE POST WITH ACCESSORY POSTS

*Now, in the case where the coronal circumference has a wide flare of more than 50% greater than that of the largest fiber post available, or the practitioner is working with a ribbon, ovoid, or triangular canal, the suggested technique is as follows:*

As can be seen from Figure 16a, the existing canal in which a cast post and core failed, is over-prepared and widely tapered at the coronal aspect. By following the previous methodology, the canal is prepared and the fit of the fiber post is assessed (Figure 16b). The large amount of resin cement will need to be minimized to decrease the shrinkage factor, and the cement and core material will need strengthening. The canal is etched, rinsed, and dried lightly; the compatible bonding agent is agitated into the canal (Figure 16c); and light-cured (Figure 16d). After direct injection of the dual cured resin cement (Figure 16e), the prebonded fiber post is inserted (Figure 16f), and prebonded Fibercones (RTD) are inserted (Figure

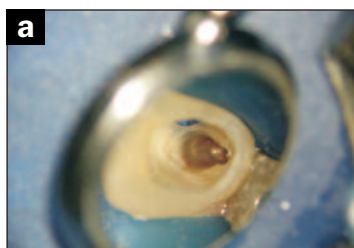
16g). Then, core composite is injected between and around the Fibercones and central “master” fiber post and hand sculpted prior to light-curing (Figure 16h). Lastly, the core build-up is shaped, light-cured, and prepared to final shape with diamonds (Figures 16i and 16j).

Figure 17a shows the typical triangular shape encountered when restoring anterior teeth. Figure 17b shows a Macro-Lock X-RO with an accessory Fibercone placed in the lingual slot area. The final clinical photograph is shown in Figure 17c. This we will call the (direct) *accessory post* technique, in which the “master” fiber post—size-selected for its fit at the apical end of the space—is accompanied by one or more slender, tapered accessory posts (eg, Fibercone). The clinician may draw an immediate parallel to their training with gutta percha cones. RTD translucent quartz fiber posts (DT Light-Post and Macro-Lock X-RO) have been shown to have limited but relatively superior transmission of the polymerization light energy<sup>56-58</sup> down

into the post-restorative space, a property which is an important attribute and would necessarily disqualify the use of many other (less conductive) fiber posts for this technique.

In addition, the flexural and compressive strength of the factory-made composite (99.9% cross-linked) are higher than a composite hand-cured by light energy at chair-

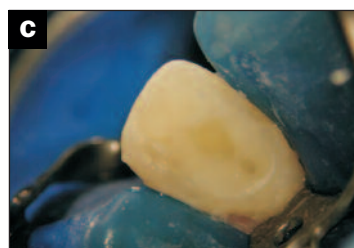
*continued on page xx*



**Figure 17a.** The typical triangular shape of anterior root canal space after endodontic preparation.



**Figure 17b.** This anatomic space is ideal for the placement of a Macro-Lock X-RO fiber post complemented with an auxiliary Fibercone to decrease the amount of dual cure resin used and fortify the restoration.



**Figure 17c.** Postoperative photograph of the Fibercone and auxiliary Fibercone in the triangular shaped canal.

## Fiber Post Techniques...

continued from page 00

side. In comparison, the cross-linked networks during polymerization and degree of conversion for most direct resin materials ranges from 45% to 70%.<sup>59</sup>

Published studies demonstrate the other benefits of this *Accessory Post* technique:

- Minimizes shrinkage in flared canals and, therefore, gap formation<sup>60</sup>
- Reduces the need for drilling in order to adapt posts to root cavity,<sup>61</sup> (minimizes dentin removal)
- Reduces the thickness of cement, and increased fracture resistance.<sup>60</sup>

Fiber posts, associated with composite resin or with accessory fiber posts, seem to be more indicated as an alternative to cast post and core in flared roots, because of the lower risk of catastrophic failures and better stress distribution.<sup>62</sup>

It is possible to conclude that use of the fiber post, associated with accessory posts, is the method of choice for reinforcing structurally weakened roots, and provides an improvement in the load carrying ability of the restored root is validated, as opposed to the use of one single inadequately fitting post.<sup>63,64</sup>

## SUMMARY

In contemporary dental practice, there is no remaining reason to use metallic posts, custom or prefabricated. Many cases that several years ago would have required a retentive post, will not require that post today, because of the many improvements in bonding agents and composite resin restoratives. However, in cases where less than 50% of coronal tooth structure remains—or in other cases wherein the judgment of the clinician a post is indicated—there are now aesthetic, non-corrosive, fracture resistant and radiopaque alternatives for all varieties that save time and money without compromise. Their most compelling advantage, regardless of the geometry or amount of residual tooth structure, is the protection from root fracture that a low modulus restoration provides.

In selecting the materials (posts, resins) for these techniques, the dentist is advised not to cut corners, and to seek the strongest and most radiopaque products available.◆

## References

1. Adanir N, Belli S. Stress analysis of a maxillary central incisor restored with different posts. *Eur J Dent.* 2007;1:67-71.
2. Albuquerque Rde C, Polleto LT, Fontana RH, et al. Stress analysis of an upper central incisor restored with different posts. *J Oral Rehabil.*

- 2003;30:936-943.
3. Lanza A, Aversa R, Rengo S, et al. 3D FEA of cemented steel, glass and carbon posts in a maxillary incisor. *Dent Mater.* 2005;21:709-715.
4. Okamoto K, Ino T, Iwase N, et al. Three-dimensional finite element analysis of stress distribution in composite resin cores with fiber posts of varying diameters. *Dent Mater J.* 2008;27:49-55.
5. Rosenstiel SF, Land MF, Fujimoto J. *Contemporary Fixed Prosthodontics*. 3rd ed. St. Louis, MO: Mosby; 2001:295.
6. Torbjörner A, Karlsson S, Odman PA. Survival rate and failure characteristics for two post designs. *J Prosthet Dent.* 1995;73:439-444.
7. Martelli R. Fourth-generation intraradicular posts for the aesthetic restoration of anterior teeth. *Pract Periodontics Aesthet Dent.* 2000;12:579-588.
8. Milnar FJ. Aesthetic treatment of dark root syndrome. *Dent Today.* September 2010;29:74-79.
9. Anderson GC, Perdigão J, Hodges JS, et al. Efficiency and effectiveness of fiber post removal using 3 techniques. *Quintessence Int.* 2007;38:663-670.
10. Cormier CJ, Burns DR, Moon P. In vitro comparison of the fracture resistance and failure mode of fiber, ceramic, and conventional post systems at various stages of restoration. *J Prosthodont.* 2001;10:26-36.
11. Frazer RQ, Kovarik RE, Chance KB, et al. Removal time of fiber posts versus titanium posts. *Am J Dent.* 2008;21:175-178.
12. Gesi A, Magnolfi S, Goracci C, et al. Comparison of two techniques for removing fiber posts. *J Endod.* 2003;29:580-582.
13. Rosenstiel SF, Land MF, Fujimoto J. *Contemporary Fixed Prosthodontics*. 3rd ed. St. Louis, MO: Mosby; 2001:275.
14. Ferrari M, Scotti R. *Fiber Posts: Characteristics and Clinical Applications*. Paris, France: Masson Publishing; 2002:26.
15. Grandini S, Goracci C, Monticelli F, et al. An evaluation, using a three-point bending test, of the fatigue resistance of certain fiber posts. *II Dentista Moderno.* March 2004;70-74.
16. Vallittu PK, Lassila VP, Lappalainen R. Acrylic resin-fiber composite—Part 1: The effect of fiber concentration on fracture resistance. *J Prosthet Dent.* 1994;71:607-612.
17. Denny D, Heaven T, Broome JC, et al. Radiopacity of luting cements and endodontic posts. *J Dent Res.* 2005;84(A, special issue). Abstract 0675.
18. McClendon K, Ripps A, Fan Y. Comparative study on radiopacity of fiber posts and resin cements. *J Dent Res.* 2010;84(A, special issue). Abstract 0253.
19. Wiskott HW, Meyer M, Perriard J, et al. Rotational fatigue-resistance of seven post types anchored on natural teeth. *Dent Mater.* 2007;23:1412-1419.
20. Sorensen JA, Ahn SG, Berge H-X, Edelhoff D. Selection criteria for post and core materials in the restoration of endodontically treated teeth. *Dent Materials.* 2001;15:67-84.
21. Wiskott WH, Nicholls JI, Belser UC. Stress fatigue: basic principles and prosthodontic implications. *Int J Prosthodont.* 1995;8:105-116.
22. Hajizadeh H, Namazikhah MS, Moghaddas MJ, et al. Effect of posts on the fracture resistance of load-cycled endodontically-treated premolars restored with direct composite resin. *J Contemp Dent Pract.* 2009;10:10-17.
23. Salameh Z, Sorrentino R, Ounsi HF, et al. The effect of different full-coverage crown systems on fracture resistance and failure pattern of endodontically treated maxillary incisors restored with and without glass fiber posts. *J Endod.* 2008;34:842-846.
24. Dikbas I, Tanalp J, Ozel E, et al. Evaluation of the effect of different ferrule designs on the fracture resistance of endodontically treated maxillary central incisors incorporating fiber posts, composite cores and crown restorations. *J Contemp Dent Pract.* 2007;8:62-69.
25. D'Arcangelo C, De Angelis F, Vadini M, et al. Fracture resistance and deflection of pulpless anterior teeth restored with composite or porcelain veneers. *J Endod.* 2010;36:153-156.
26. Hayashi M, Takahashi Y, Imazato S, et al. Fracture resistance of pulpless teeth restored with post-cores and crowns. *Dent Mater.* 2006;22:477-485.
27. Glazer B. Restoration of endodontically treated teeth with carbon fibre posts—a prospective study. *J Can Dent Assoc.* 2000;66:613-618.
28. Schmitter M, Rammelsberg P, Gabbert O, et al. Influence of clinical baseline findings on the survival of 2 post systems: a randomized clinical trial. *Int J Prosthodont.* 2007;20:173-178.
29. Ferrari M, Vichi A, Mannocci F, et al. Retrospective study of the clinical performance of fiber posts. *Am J Dent.* 2000;13(special issue):9B-13B.
30. Fazekas A, Menyhárt K, Bódi K, et al. Restoration of root canal treated teeth using carbon fiber posts [in Hungarian]. *Fogorv Sz.* 1998;91:163-170.
31. Cagidiaco MC, Radovic I, Simonetti M, et al. Clinical performance of fiber post restorations in endodontically treated teeth: 2-year results. *Int J Prosthodont.* 2007;20:293-298.
32. Ferrari M, Cagidiaco MC, Grandini S, et al. Post placement affects survival of endodontically treated premolars. *J Dent Res.* 2007;86:729-734.
33. Grandini S, Goracci C, Tay FR, et al. Clinical evaluation of the use of fiber posts and direct resin restorations for endodontically treated teeth. *Int J Prosthodont.* 2005;18:399-404.
34. Cagidiaco MC, Goracci C, García-Godoy F, et al. Clinical studies of fiber posts: a literature review. *Int J Prosthodont.* 2008;21:328-336.
35. Ferrari M, Cagidiaco MC, Goracci C, et al. Long-term retrospective study of the clinical performance of fiber posts. *Am J Dent.* 2007;20:287-291.
36. Ferrari M, Vichi A, García-Godoy F. Clinical evaluation of fiber-reinforced epoxy resin posts and cast post and cores. *Am J Dent.* 2000;13(special issue):15B-18B.
37. Naumann M, Blankenstein F, Dietrich T. Survival of glass fibre reinforced composite post restorations after 2 years—an observational clinical study. *J Dent.* 2005;33:305-312.
38. Signore A, Benedicenti S, Kaitsas V, et al. Long-term survival of endodontically treated, maxillary anterior teeth restored with either tapered or parallel-sided glass-fiber posts and full-ceramic crown coverage. *J Dent.* 2009;37:115-121.
39. Dietschi D, Duc O, Krejci I, et al. Biomechanical considerations for the restoration of endodontically treated teeth: a systematic review of the literature—Part 1. Composition and micro- and macrostructure alterations. *Quintessence Int.* 2007;38:733-743.
40. Baldissara P, Zicari F, Ciocca L, et al. Effect of fiber post emerging diameter on composite core stabilization. *J Dent Res.* 2007;86(A, special issue). Abstract 2623.
41. Boudrias P, Sakkal S, Petrova Y, et al. Anatomical post design applied to quartz fiber/epoxy technology: a conservative approach. *Oral Health.* 2001;91:9-20.
42. Rosenstiel SF, Land MF, Fujimoto J. *Contemporary Fixed Prosthodontics*. 3rd ed. St. Louis, MO: Mosby; 2001:279.
43. Breschi L, Mazzoni A, De Stefano D, et al. Adhesion to intraradicular dentin: a review. *Journal of Adhesion Science and Technology.* 2009;23:1053-1083.
44. Rodríguez-Cervantes PJ, Sancho-Bru JL, Barjau-Escribano A, et al. Influence of prefabricated post dimensions on restored maxillary central incisors. *J Oral Rehabil.* 2007;34:141-152.
45. Mazzoni A, Marchesi G, Cadenaro M., et al. Push-out stress for fibre posts luted using different adhesive strategies. *Eur J Oral Sci.* 2009;117:447-453.
46. Kremeier K, Fasen L, Klaiber B, et al. Influence of endodontic post type (glass fiber, quartz fiber or gold) and luting material on push-out bond strength to dentin in vitro. *Dent Mater.* 2008;24:660-666.
47. Akgungor G, Akkayan B. Influence of dentin bonding agents and polymerization modes on the bond strength between translucent fiber posts and three dentin regions within a post space. *J Prosthet Dent.* 2006;95:368-378.
48. Radovic I, Monticelli F, Goracci C, et al. Self-adhesive resin cements: a literature review. *J Adhes Dent.* 2008;10:251-258.
49. Baldissara P, Monaco C, Valandro LF, et al. Retention of quartz fiber posts using different luting cements. *J Dent Res.* 2009;88(A, special issue). Abstract 976.
50. Ferrari M, Carvalho CA, Goracci C, et al. Influence of luting material filler content on post cementation. *J Dent Res.* 2009;88:951-956.
51. Grande NM, Butti A, Plotino G, et al. Adapting fiber-reinforced composite root canal posts for use in noncircular-shaped canals. *Pract Proced Aesthet Dent.* 2006;18:593-599.
52. Plotino G, Grande NM, Pameijer CH, et al. Influence of surface remodelling using burs on the macro and micro surface morphology of anatomically formed fibre posts. *Int Endod J.* 2008;41:345-355.
53. Ferrari M, Scotti R. *Fiber Posts: Characteristics and Clinical Applications*. Paris, France: Masson Publishing; 2002:94-95.
54. Iglesia-Puig MA, Arellano-Cabornero A. Fiber-reinforced post and core adapted to a previous metal ceramic crown. *J Prosthet Dent.* 2004;91:191-194.
55. Grandini S, Sapio S, Simonetti M. Use of anatomical post and core for reconstructing an endodontically treated tooth: a case report. *J Adhes Dent.* 2003;5:243-247.
56. Miller MB. Fiber posts. In: *Reality Now*. Houston, TX: Reality Publishing; 2006: 643-660.

57. Christensen GJ. Posts a shift away from metal? *CRA Newsletter.* 2004;28(5):1-3.
58. Goracci C, Corciolani G, Vichi A, et al. Light-transmitting ability of marketed fiber posts. *J Dent Res.* 2008;87:1122-1126.
59. Lambert D. A "recipe for success" with posterior composites utilizing preheated resins. *Oral Health.* 2009;99:67.
60. Porciani PF, Vano M, Radovic I, et al. Fracture resistance of fiber posts: combinations of several small posts vs. standardized single post. *Am J Dent.* 2008;21:373-376.
61. Maceri F, Martignoni M, Vairo G. Mechanical behaviour of endodontic restorations with multiple prefabricated posts: a finite-element approach. *J Biomech.* 2007;40:2386-2398.
62. Raposo LHA, Silva GR, Santos-Filho PCF, et al. Effect of posts and materials on flared teeth's mechanical behavior. *J Dent Res.* 2008;87(B, special issue). Abstract 1862.
63. Braz R, Conceição AAB, Conceição EN, et al. Evaluation of reinforcement materials used on filling of weakened roots. *J Dent Res.* 2005;84(A, special issue). Abstract 1733.
64. Porciani PF, Grandini S, Papacchini F, et al. The fit of two fiber posts into the root canal space enlarged with rotary NiTi files at four different levels. *International Dentistry S Afr.* 2007; 9(1):44-50.

**Dr. Boksman** is an adjunct clinical professor at the Schulich School of Medicine and Dentistry, and has a private practice in London, Ontario, Canada. He can be reached at lboksman@clinicalresearchdental.ca.

*Disclosure: Dr. Boksman is a paid part-time consultancy position as the director of clinical affairs for Clinical Research Dental and CLINICIAN'S CHOICE.*

**Dr. Hepburn** works as adjunct professor at the operative dentistry department of the University of Buenos Aires Dental School (Buenos Aires, Argentina), and at the Oral Rehabilitation Postgraduate Career in the University del Desarrollo Dental School (Concepción, Chile). He has a private practice in Buenos Aires, Argentina. Dr. Hepburn can be reached at hepburn@speedy.com.ar.

*Disclosure: Dr. Hepburn is a consultant for VOCO GmbH (Germany).*

**Dr. Kogan** works as a professor of Restorative Dentistry Universidad Tecnológica de Mexico, visiting professor Nova Southeastern University College of Dental Medicine, Fort Lauderdale, Fla and has a private practice in Mexico City, Mexico. Dr. Kogan can be reached at ekoganf@gmail.com.

*Disclosure: Dr. Kogan is the designer and patent owner of the PeerlessPost (SybronEndo).*

**Dr. Friedman** maintains a private practice limited to endodontics in London, Ontario, Canada, and is assistant adjunct professor in the division of restorative dentistry at the University of Western Ontario, London, Canada. He can be reached via e-mail at ndofriedman@rogers.com.

*Disclosure: Dr. Friedman reports no disclosures.*

**Dr. De Rijk** was formerly in the department of restorative dentistry at the University of Tennessee Health Science Center Memphis, Tenn. He is currently an associate professor of Restorative Dentistry and Chief of the Biomaterials Unit at the School of Dental Medicine East Carolina University. He can be reached at (252) 737-7020 or via e-mail at derijkw@ecu.edu.

*Disclosure: Dr. De Rijk reports no disclosures.*

continued on page xx

**Fiber Post Techniques...**  
*continued from page 00*

---

*continued on page xx*